



# Impingement around the hip: beyond cam and pincer

Niels Hendrik Bech  
Daniel Haverkamp

- In this review, we bring to the attention of the reader three relatively unknown types of hip impingement. We explain the concept of low anterior inferior iliac spine (AIIS) impingement, also known as sub-spine impingement, ischio-femoral impingement (IFI) and pelvi-trochanteric impingement. For each type of impingement, we performed a search of relevant literature.
- We searched the PubMed, Medline (Ovid) and Embase databases from 1960 to March 2016. For each different type of impingement, a different search strategy was conducted.
- In total, 19 studies were included and described. No data analysis was performed since there was not much comparable data between studies.
- An overview of symptoms, clinical tests and possible surgical treatment options for the three different types of extra-articular impingement is provided.
- Several disorders around the hip can cause similar complaints. Therefore, we plead for a standardized classification. In young and athletic patients, in particular, there is much to gain if hip impingement is diagnosed early.

**Keywords:** hip; impingement; arthroscopy

Cite this article: *EFORT Open Rev* 2018;3:30-38.

DOI: 10.1302/2058-5241.3.160068

## Introduction

The concept of impingement is not a new one and can be found in orthopaedic textbooks predating 1900. Interest in hip impingement increased considerably after hip arthroscopy was accepted as a feasible treatment possibility. Burman was the first to look inside the hip and performed arthroscopy of the hip in cadavers.<sup>1</sup> Since he used no distraction, it was not very successful and clinical interest in arthroscopy declined. During the last several decades, the number of publications on hip arthroscopy and

hip impingement has grown steadily. Now cam (Fig. 1) and pincer impingement are recognized as entities that are treatable and are seen and recognized by many orthopaedic surgeons and not just hip specialists.

It is now time to draw attention to the more unusual types of impingement, since these are often not recognized in general orthopaedic practice.

This review discusses three types of lesser-known causes of hip impingement and the current literature.

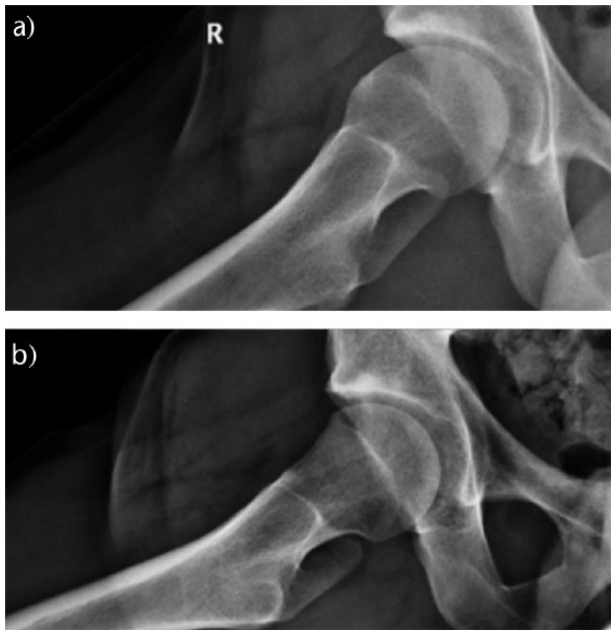
## Classical impingement: cam and pincer

The definition of femoro-acetabular impingement (FAI) using the distinction between cam and pincer was made by Ganz et al. In 1991, they described a group of six patients with FAI-type complaints after a fracture of the femoral neck.<sup>2</sup> Since then, several articles have been published reviewing FAI (Fig. 2) and the terms 'cam' and 'pincer' have been introduced.

FAI is normally morphologically subdivided into two types, cam and pincer, although a number of patients show signs of both types simultaneously, also known as the 'combined' or 'mixed' types.

The cam type is characterized by femoral head/neck junction malformations that result in shearing forces on the labrum and the articular cartilage (Fig. 1). The impingement can be caused by a congenital hip problem but mostly no pre-existing cause is found.<sup>3</sup> Cam-type FAI is most often found in young, athletic men.<sup>4</sup>

Pincer impingement is more common in middle-aged athletic women.<sup>4</sup> In these patients, the acetabulum covers too much of the femur head (Fig. 3). General over-coverage of the femoral head is seen in a protrusion acetabuli or as part of an overgrowth of the anterior wall. Another cause of pincer impingement is seen in cases of acetabular retroversion (normal acetabular anteversion is 15° to 20°).<sup>5</sup> Acetabular retroversion causes over-coverage of the anterior wall, seen as a 'cross-over' sign on the radiograph (Fig. 3).<sup>6,7</sup>



**Fig. 1** a) Cam-type impingement before hip arthroscopy; b) same patient after arthroscopic cam resection.

The combined or mixed type shows morphologies of both cam and pincer simultaneously and is quite common in most studies.<sup>8,9</sup> Cam and pincer impingement are well-known indications for hip arthroscopy and many publications can be found related to this topic. However, we must bear in mind and realize that these are just the intra-articular causes for hip impingement.

Arthroscopic treatment of FAI in the literature is shown to be effective in terms of short-term pain relief and functional outcome.<sup>3,10-12</sup> Arthroscopic osteoplasty is equally

effective as open surgical dislocation for anterior and antero-superior cam and focal rim impingement lesions, but post-operative recovery is faster compared with the open procedure and early correction of FAI improves hip pain.<sup>4,13</sup>

A study by Beck et al in 2004 of 158 patients showed that most patients reported 95% of their pain resolved one year after hip arthroscopy.<sup>14</sup> Primary arthroscopic decompression is now accepted as a successful procedure with low rates of major and minor complications. There is, however, a learning curve for performing hip arthroscopy.<sup>9,15</sup> Hip arthroscopy is successful in the majority of patients, but sometimes revision hip arthroscopy has to be performed. The main reason for revision arthroscopy is incomplete correction and persistence of residual deformity.<sup>16,17</sup>

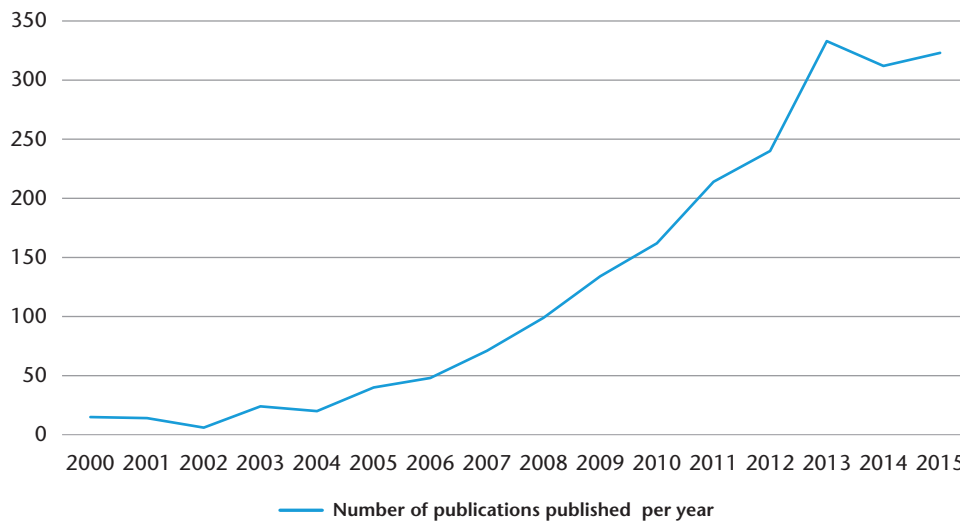
Although there is evidence that surgery can improve symptoms in the short term, there still is no evidence that it slows the development of osteoarthritis (OA).

## Materials and methods

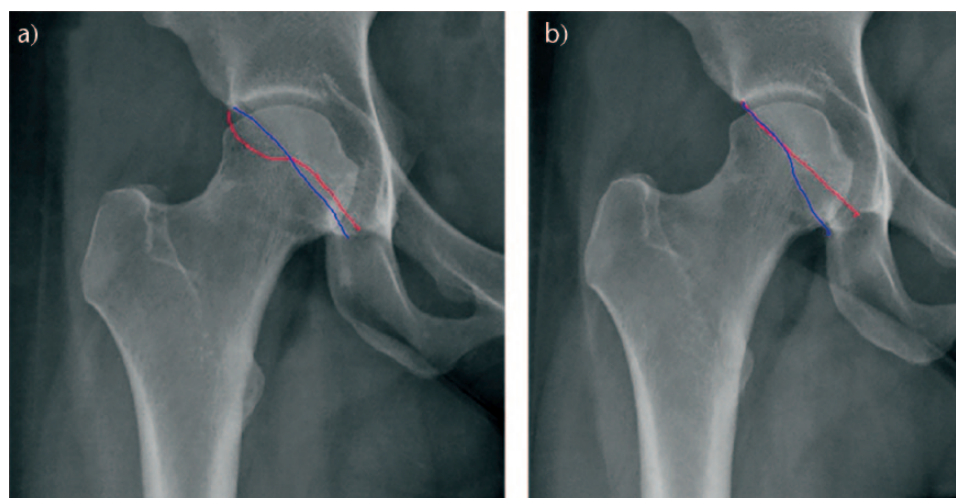
A research protocol was developed as described by Wright et al and used throughout the study process.<sup>18</sup> This protocol was not registered. A literature search was performed of the PubMed, Medline (Ovid) and Embase databases from 1960 to March 2016.

For each different type of impingement, a different search strategy was conducted.

For the low anterior inferior iliac spine (AIIS) impingement, the following search terms were used: ((femoracetabular impingement OR impingement OR avulsion) and (subspine OR ssi OR anterior inferior iliac)).



**Fig. 2** Number of FAI publications published every year.



**Fig. 3** a) Pincer-type impingement before hip arthroscopy. The red line shows the anterior wall, the blue line the posterior wall. A cross-over sign is present. Also note the visible ischial spine sign. b) Same patient after arthroscopic decompression.

**Table 1.** Articles on surgical treatment for AIIS

Author	Sample size	Surgical intervention	Follow up	Preoperative outcome	Postoperative outcome	Significance
Larson et al <sup>46</sup>	3 patients	Arthroscopic decompression of AIIS with/without osteoplasty and labral repair	Mean $\pm$ SD 16 $\pm$ 3.5 months (range 12-18 months)	Mean HHS 76 (range 74-79) Mean VAS 6.2 (range 4.85-8.0)	Mean HHS 94 (range 85-100) Mean VAS 1.1 (range 0.0-1.75)	
Hapa et al <sup>9</sup>	163 hips	Arthroscopic decompression of the AIIS with/without CAM resection/rim trim/labral repair with/without other procedures	Mean $\pm$ SD 11.1 $\pm$ 4.1 months (range 6-12 months)	Mean modified HHS 63.1 (range 21-90) SF- 12, mean 70.4 (range 34-93) VAS 4.9 (range 0.1-8.6)	Mean modified HHS 85.3 (range 37-100) SF- 12, mean 81.3 (range 31-99) VAS 1.9 (range 0-7.8)	HHS (p < .01) SF- 12 (p < .01) VAS (p < .01)
Amar et al <sup>48</sup>	1 patient	Arthroscopic rim resection, labral re-fixation and AIIS and femoral osteoplasty	6 weeks	Not reported	Relief of pain	
Hetsroni et al <sup>23</sup>	10 patients	Arthroscopic decompression of AIIS plus cam resection with/without rim trim plus labral repair or debridement	Mean $\pm$ SD, 14.1 $\pm$ 7.2 mo (range 6-26 mo)	Flexion ROM 99 $\pm$ 7 Modified HHS 64 $\pm$ 18	Flexion ROM 117 $\pm$ 8 Modified HHS 98 $\pm$ 2	Flexion ROM (p < .001) Modified HHS (p < .001)
Pan et al <sup>19</sup>	1 patient	Open procedure: detachment of the tensor fascia lata and gluteus medius from iliac crest, detachment of heads of rectus femoris, arthrotomy, AIIS resection	5 weeks	Not reported	Hip flexion 120°, normal range of internal rotation Relief of pain	
Rajasekhar et al <sup>22</sup>	1 patient	Open resection of exuberant callus	30 months	Groin pain, aggravated by flexion of the hip, normal range of movement of both hips	Completely asymptomatic	
Irving <sup>21</sup>	1 patient	Open resection of exostosis	Not reported	Moderate limitation of rotation and abduction of the hip	Full range of hip movement	
Matsuda et al <sup>47</sup>	1 patient	Arthroscopic 'spinoplasty' plus CAM resection plus rim trim plus labral re-fixation	18 months	Hip flexor strength 4/5, non-arthritis hip score 22, internal rotation 20°	Hip flexor strength 5/5, non-arthritis hip score 98, no restriction hip motion	

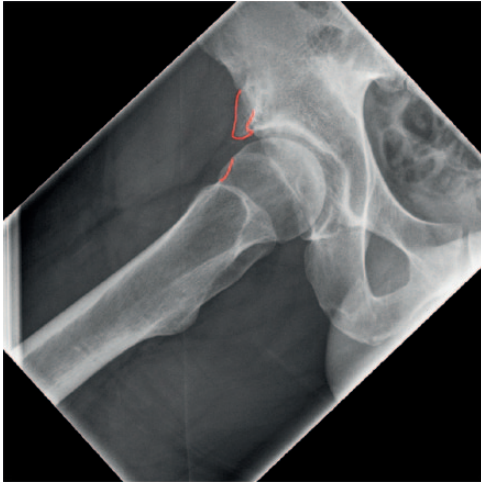
HHS, Harris Hip Score; VAS, visual analogue scale; ROM, range of motion.

For ischiofemoral impingement (IFI), the search contained the terms: ((femoracetabular impingement OR impingement OR avulsion) and (ischiofemoral)).

For the pelvitrochanteric-type impingement, the search terms were: ((femoracetabular impingement OR impingement OR avulsion) and (trochanter OR pelvitrochanter OR

greater trochanter OR psoas OR iliopsoas OR snapping hip)).

Articles were deemed eligible if the study was of patients aged 12 years and older and who had undergone surgical treatment for one of the three types of impingement. Only surgical studies were included. Radiographic



**Fig. 4** Low AIIS impingement type III.

analysis studies, reviews, course lectures and cadaveric studies were excluded. Furthermore, only English language studies were included.

Two investigators (NB and DH) independently reviewed the literature to identify relevant articles for full review. From the full text, using the above-mentioned criteria, the reviewers independently selected articles for inclusion in this review. The lists of references of retrieved publications were manually checked for additional studies potentially meeting the inclusion criteria but not found by the electronic search.

Disagreements were addressed by discussion between reviewers 1 and 2 and conflicts were resolved.

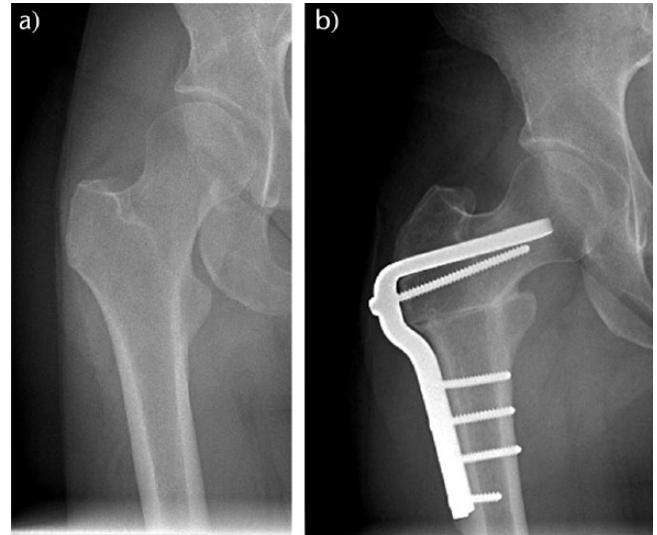
No data analysis was performed since there was not much comparable data between studies.

#### *Anterior inferior iliac spine impingement*

Besides the classical impingement types, there are also some types of extra-articular impingement. The first is AIIS impingement or sub-spine impingement (SSI). In the literature, not much can be found about this type of impingement and it is unknown to many clinicians who are seeing patients with groin pain. Similarly, little literature is available discussing AIIS impingement or SSI, and even less about treatment options (Table 1).

Pan et al first described it as an impingement type in 2008.<sup>19</sup> In this type of extra-articular impingement, the femoral neck or head/neck junction impinges on the AIIS (Fig. 4); the AIIS can be too large due to hypertrophy, previous avulsion or corrective osteotomies. Symptoms are identical to cam or pincer impingement, being groin pain on flexion and internal rotation, but with local tenderness over the AIIS and incomplete pain relief on intra-articular Marcaine injection (as a diagnostic test).

In a CT-scan study by Hetsroni et al, three types of AIIS impingement were defined: in type I, there is a smooth



**Fig. 5** a) IFI in a valgus hip; b) a possible solution could be a varus intertrochanteric osteotomy.

ilium wall without bony prominences between the caudal level of the AIIS and the anterior-superior acetabular rim;<sup>20</sup> in type II, there are bony prominences on the ilium wall extending from the caudal area of the AIIS to the acetabular rim, or alternatively the AIIS appears as a 'roof-like' prominence over the hip at the level of the acetabular rim; and in type III, the AIIS extends distally to the antero-superior acetabular rim. In this case, the AIIS interferes with the continuity of the acetabular rim on CT imaging on the anteroposterior (AP) view or 'head-on AIIS view' or both, and it has a downward 'spur appearance'. Types II and III are associated with a decreased range of motion of hip flexion and internal rotation.

AIIS can be addressed surgically via an open or arthroscopic treatment. The open approach results in excellent pain relief and restoration of hip movement, but is only described in case reports.<sup>19,21,22</sup> Later studies describe excellent short-term outcomes for arthroscopic decompression at the level of the anterior rim.<sup>9,23,48</sup> Short-term outcomes of surgical decompression of the AIIS prominence may be favourable for patients with characteristic anterior hip pain worsened with straight leg hip flexion.<sup>24</sup>

In the study by Hetsroni et al, all patients had AIIS impingement combined with at least one other abnormal intra-articular finding (cam lesions, labral tears or rim lesions). Particularly in the patients with mixed intra- and extra-articular components that cause AIIS, arthroscopy is preferable compared with an open procedure since the surgeon is able to address all pathologies in a single arthroscopic procedure.<sup>23</sup> As a more aggressive decompression, a small longitudinal split of the rectus tendon is also described, which can result in the complication of a detachment of the rectus femoris muscle.<sup>9</sup> To conclude,



**Table 2.** Articles on surgical treatment for IFI

Author	Sample size	Surgical intervention	Follow up	Preoperative outcome	Postoperative outcome	Significance
Hatem et al <sup>26</sup>	5 patients	Endoscopic partial resection of the quadratus muscle, osteoplasty of the lesser trochanter	2.3 years (range 2-2.5)	Mean modified HHS 51.3 (range 34.1-73.7) VAS 6.6 (range 6-7.3) iHOT score 32	Mean modified HHS 94.2 (range 78.1-100) VAS 1 (range 0-4) iHOT score 85 Pain relief, no involuntary snapping	HHS p = .003 VAS p = .001
Safran et al <sup>32</sup>	1 patient	Endoscopic iliopsoas bursectomy, total resection of iliopsoas muscle and tendon from the lesser trochanter, excision of the lesser trochanter	2 years			
Viala et al <sup>30</sup>	1 patient	Open resection of exostosis	6 months	Maximal hip flexion at 100°, internal rotation 10–20°, external rotation 40°, and abduction 45°	Hip pain improvement	
Ali et al <sup>31</sup>	1 patient	Open resection of lesser trochanter	10 weeks	Audible snapping	No pain No snapping of quadratus femoris No impingement intraoperatively in neutral position of hip in extension	
Ganz et al <sup>33</sup>	8 hips	Osteotomy of lesser trochanter, mobilizing and distalizing the fragment and fixation with 2 screws	3.5 years	3 patients hip instability	All hips were healed at 2.5 years follow up	
Wilson et al <sup>34</sup>	7 patients	All patients iliopsoas tendon release followed by lesser trochanter resection.	Average 20 months	mHHS: average 43 range 20-76	6 weeks: average 58 6 months: average 86 12 months: average 91 (range 76-100)	Not mentioned

iHOT, International Hip Outcome Tool; HHS, Harris Hip Score; VAS, visual analogue scale.

there is evidence that surgical intervention leads to good results regarding pain and hip movement, but the evidence is scarce and mostly based on case reports.

### Ischiofemoral impingement

Another form of extra-articular impingement is IFI, which was first described by Johnson in 1977 as an iatrogenically induced condition following total hip arthroplasty (THA).<sup>43</sup> Unlike FAI, it is an extra-articular process and there is no direct relationship with acetabular labral tears or chondral damage. This type of impingement occurs when the distance between the lesser trochanter and ischium is too narrow, causing impingement squeezing of the quadratus femoris muscle (Fig. 5).<sup>44</sup> The normal distance between the lesser trochanter and os ischium is described as being approximately 2 cm.<sup>25</sup> Narrowing of this space can occur in extreme valgus hips or from iatrogenic causes, for instance, by offset loss after THA or extreme valgisation after hip osteotomy.

Patients with IFI report deep gluteal pain as a major complaint.<sup>26</sup> Clinical tests for IFI are the long-stride walking test and IFI test.<sup>26</sup> The long-stride walking test intends to provoke IFI and is considered positive if the patient grabs the affected hip during extension and when pain is relieved during hip abduction (considering the fact that during hip abduction, the ischiofemoral space widens) or when walking shorter strides [26]. The IFI test is performed with the patient in the contralateral decubitus position and the test is positive when patients complain of the known pain during passive extension and adduction (or

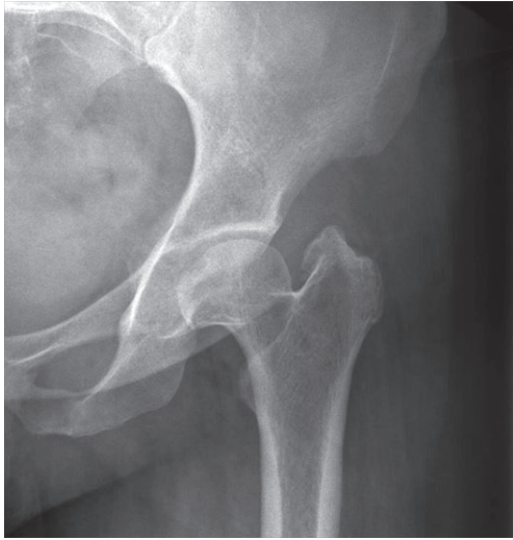neutral) position of the affected hip.<sup>26</sup> During passive extension and abduction, patients are relieved of their buttock pain.<sup>26</sup>

Papers reporting IFI that use MRI show that the space between the ischial tuberosity and lesser trochanter is narrowed; in some cases, this can also be caused by femoral rotation (for example, in coxa valga hips). It is important to pay attention to atrophy, inflammation or oedema of the quadratus femoris muscle on the MRI scan since these findings suggest IFI.<sup>25,27,45</sup>

Little has been published about treatment options and there is no consensus yet on the optimal treatment for IFI. In 1977, Johnson suggested excision of the lesser trochanter. Ultrasound-guided steroid injection of the quadratus femoris muscle shows promise as a part of conservative treatment.<sup>28,29</sup>

Only a few studies are published which provide information about surgical treatment options for IFI, using an open procedure or arthroscopy (Table 2).<sup>26,30-34</sup> These studies provide limited, low quality evidence suggesting surgical intervention to widen the ischiofemoral space by lesser trochanteric excision or ischial tuberosity decompression that may lead to clinical benefit, with minimal risk.<sup>24,30,31,33</sup>

Most often, the available research focuses on resection of the lesser trochanter. However, in cases which are iatrogenic, IFI occurs after total hip replacement (THR) because of loss of offset, and a revision of the THR might be a more suitable solution. For extreme coxa valga, restoration of the caput-collum diaphyseal angle (CCD) and offset by



**Fig. 6** Left hip of a 45-year-old woman with pelvitrochanteric impingement. Note the high-riding trochanter and short femoral neck.

performing a classical varus intertrochanteric osteotomy is, in our opinion, a surgical intervention that should not be forgotten.

#### *Pelvitrochanteric impingement*

Besides AIIS and IFI, there is the pelvic-greater trochanter type impingement. This type of impingement is most often seen in patients who suffered from Legg-Calve-Perthes disease, congenital dislocation or a slipped capital femoral epiphysis (SCFE), which can result in a shortened femoral neck, a more prominent greater trochanter in a relative proximal position and a deformed aspherical head (Fig. 6). This causes impingement between the ilium and greater trochanter during abduction of the hip. Patients complain of pain during walking and symptoms are limping, abductor weakness and decreased range of motion.<sup>35</sup>

Standard diagnostic evaluation includes AP pelvic radiograph and lateral radiograph of the proximal femur.<sup>35</sup>

The first operative treatment option was described by Jani in 1969 and consisted of a lateralizing osteotomy of the greater trochanter.<sup>36</sup> In 1991, Macnicol and Makris described the typical gear stick sign used to diagnose pelvitrochanteric impingement. During flexion of the hip, full abduction is possible, but when the hip is in full extension, the prominent greater trochanter impinges against the ilium or posterior rim of the acetabulum.<sup>37</sup> Furthermore, they reported a new satisfying technique in which they distalized the greater trochanter after performing a trochanteric osteotomy. In their review, they report 27 procedures performed over 22 years (Table 3). In all cases, the greater trochanter united without delay. All patients had a positive Trendelenburg sign pre-operatively. Overall, gait improved

and most patients reported complete pain relief post-operatively. In some patients with persistent pain, this was mostly due to the development of OA.

Leunig and Ganz reported 14 femoral head reduction osteotomies being performed as a safe and satisfactory technique for Perthes or Perthes-like deformities.<sup>38</sup> Of these 14 patients, eight received an additional pelvic acetabular osteotomy. All osteotomies healed and united without problems and all patients reported satisfying results regarding pain relief.

More recently, a study by Albers et al retrospectively reviewed the results of relative femoral neck lengthening for 41 hips in 40 patients who underwent surgery between 1998 and 2006.<sup>35</sup> In this group, the proximal femoral deformities were the sequelae of Legg-Calve-Perthes disease in 38 hips (93%), slipped capital femoral epiphysiolysis in two hips (5%) and post-septic arthritis in one hip (2%).

Surgery consisted of a greater trochanter osteotomy with reduction of the stable part of the greater trochanter and advancement of the greater trochanter to the proximal femur fixed with multiple screws. Osteochondroplasty of the femoral head-neck area was performed in all hips to reduce offset. Overall functional and radiographic outcomes were satisfactory (Table 3).

In patients with healed Legg-Calve-Perthes hips, there is usually a combination of intra-articular and extra-articular impingement. In the studies by Anderson et al and Shore et al, a combination of femoral head-neck osteochondroplasty and relative femoral neck lengthening by a trochanteric osteotomy was performed.<sup>39,40</sup> In 19 patients with extra-articular impingement, a trochanteric osteotomy with relative femoral neck lengthening was performed. The osteochondroplasty was done to remove the aspherical femoral head to reduce intra-articular impingement. Both studies showed a significant increase in the Harris Hip Score and WOMAC.

## **Discussion**

In this review, we have given an overview of three extra-articular types of hip impingement that are as yet unknown to the majority of orthopaedic surgeons. It is important when seeing patients with hip or groin pain for which no clear reason can be found to consider these diagnoses or send the patients to a hip specialist.

As with all new concepts, it is difficult to prove that extra-articular hip impingement really exists. Cam and pincer impingement are finally recognized as entities that are treatable and are seen by every orthopaedic surgeon and not just the hip enthusiasts. Now we hope for the same clarification for IFI, SSI and pelvitrochanteric impingement. Previous research on diagnostics and anatomical deformations concludes that it is very

**Table 3.** Articles on outcomes for the surgical treatment of pelvitrochanteric impingement

Author	Sample size	Surgical intervention	Follow up	Preoperative outcome	Postoperative outcome	Significance
Macnicol et al <sup>37</sup>	27 hips (26 patients)	11 derotation osteotomy 15 varus/valgus osteotomy 15 Salter innominate osteotomies, 4 Chiari pelvic osteotomy 1 Wainwright shelf operation	8 years (range 2-22 yrs)	All patients positive Trendelenburg test	81.5% negative Trendelenburg test 2 years after operation Passive abduction increased by an average of 15° in 13 hips (48%). Remained the same in 10 hips (37%) and decreased in 4 hips (15%). 74% (20 hips) reported complete pain relief Improved motion without substantial pain	
Leunig et al <sup>38</sup>	14 hips (13 with Perthes or Perthes-like deformities)	14 head reduction osteotomies 1 Colonna procedure 8 pelvic acetabular osteotomies	Min. 3 years			
Albers et al <sup>35</sup>	41 hips (40 patients)	Relative femoral neck lengthening with additional osteochondroplasty of head-neck area	Min. 5 years (mean 8 years, range 5-13)	Flexion ROM 94° Extension ROM 4° Internal rotation ROM 18° External rotation ROM 25° Abduction ROM 24° Adduction ROM 18° Anterior impingement test 93% positive Abductor strength 17% Limping 76% Radiographic: normal trochanteric height (% of hips): 5	Flexion ROM mean 93° Extension ROM 7° Internal rotation ROM 25° External rotation ROM 32° Abduction ROM 37° Adduction ROM 13° Anterior impingement test 49% positive Abductor strength 91% Limping 9% Radiographic: normal trochanteric height (% of hips): 80	Flexion p = .466 Extension p = .121 Internal rotation p = .045 External rotation p = .013 Abduction p = .004 Adduction p = .176 Anterior impingement test p = .002 Abductor strength p = .001 Limping p < .001 Radiographic: normal trochanteric height (% of hips): p < .001
Anderson et al <sup>39</sup>	14 hips (14 patients)	All patients underwent surgical dislocation, osteochondroplasty and trochanteric advancement	Mean 45 months	HHS: mean 66 Limping: 11 patients	HHS: mean 87	HHS p < .0001
Shore et al <sup>40</sup>	29 hips (29 patients)	All patients: femoral head-neck osteochondroplasty 19 relative femoral neck lengthening 12 intertrochanteric osteotomy 5 labral debridement 1 periacetabular osteotomy	Min. 1 year (mean 36 months, range 12-70 months)	WOMAC pain mean 8.4 WOMAC function mean 21.2 WOMAC stiffness mean 3.7	WOMAC pain mean 3.5 WOMAC function 12.5 WOMAC stiffness 2.0	WOMAC pain p < .0001 WOMAC function p = .0009 WOMAC stiffness p = .004

plausible to say that IFI, SSI and pelvitrochanteric impingement do indeed exist.<sup>20,41,42</sup> For AIIS impingement, there is a consensus on classification based on CT imaging.<sup>20</sup> Also, a very recent study concludes that MRI is a useful method for assessing the osseous and soft-tissue abnormalities associated with IFI and also for quantifying anatomical variations in pelvic morphology that can predispose to IFI.<sup>42</sup>

## Conclusions

Several disorders around the hip can cause similar complaints. Therefore, we plead for a standardized description and classification. This includes a thorough medical history, assessment of symptoms, clinical examination, standard AP pelvic radiographs and frog-leg lateral radiographs. If necessary, an additional MRI or intra-articular injection of Marcaine can help in making the right diagnosis. If one suspects a patient of having a rare type of

extra-articular impingement, this paper provides relevant information regarding clinical examination, diagnostic tests and treatment options.

There is much to gain if hip impingement is diagnosed early, especially in young and athletic patients. In medicine, in general, you can only make the diagnosis you were considering to begin with. So, unless you have recognized the more uncommon types of hip impingement, you are unlikely to diagnose them.

### AUTHOR INFORMATION

Slotervaart Center of Research and Education, The Netherlands

Correspondence should be sent to: N. H. Bech, Slotervaart Center of Research and Education – Orthopedics, Louwesweg 6, Amsterdam 1066 EC, The Netherlands.  
Email: niels.bech@gmail.com

# ICMJE CONFLICT OF INTEREST STATEMENT

Daniel Haverkamp declares consultancy for Arthrex, IMove, Implantcast, Mathys, Medichanical and Alphamed, activities outside the submitted work.

# FUNDING

No benefits in any form have been received or will be received from a commercial party related directly or indirectly to the subject of this article.

# LICENCE

© 2018 The author(s)

This article is distributed under the terms of the Creative Commons Attribution-Non Commercial 4.0 International (CC BY-NC 4.0) licence (<https://creativecommons.org/licenses/by-nc/4.0/>) which permits non-commercial use, reproduction and distribution of the work without further permission provided the original work is attributed.

# REFERENCES

- Burman MS.** Arthroscopy or the direct visualization of joints. An experimental cadaver study. *J Bone Joint Surg* 1931;13A:669–695.
- Ganz R, Bamert P, Hausner P, Isler B, Vreva F.** [Cervico-acetabular impingement after femoral neck fracture]. *Unfallchirurg* 1991;94:172–175.
- Polat G, Dikmen G, Erdil M, Aşık M.** Arthroscopic treatment of femoroacetabular impingement: early outcomes. *Acta Orthop Traumatol Turc* 2013;47:311–317.
- Crawford JR, Villar RN.** Current concepts in the management of femoroacetabular impingement. *J Bone Joint Surg [Br]* 2005;87:1459–1462.
- Tönnis D, Heinecke A.** Acetabular and femoral anteversion: relationship with osteoarthritis of the hip. *J Bone Joint Surg [Am]* 1999;81:1747–1770.
- Agricola R, Heijboer MP, Roze RH, et al.** Pincer deformity does not lead to osteoarthritis of the hip whereas acetabular dysplasia does: acetabular coverage and development of osteoarthritis in a nationwide prospective cohort study (CHECK). *Osteoarthritis Cartilage* 2013;21:1514–1521.
- Hingsammer AM, Bixby S, Zurakowski D, Yen YM, Kim YJ.** How do acetabular version and femoral head coverage change with skeletal maturity? *Clin Orthop Relat Res* 2015;473:1224–1233.
- Beck M, Kalhor M, Leunig M, Ganz R.** Hip morphology influences the pattern of damage to the acetabular cartilage: femoroacetabular impingement as a cause of early osteoarthritis of the hip. *J Bone Joint Surg [Br]* 2005;87:1012–1018.
- Hapa O, Bedi A, Gursan O, et al.** Anatomic footprint of the direct head of the rectus femoris origin: cadaveric study and clinical series of hips after arthroscopic anterior inferior iliac spine/subspine decompression. *Arthroscopy* 2013;29:1932–1940.
- Matsuda DK, Carlisle JC, Arthurs SC, Wierks CH, Philippon MJ.** Comparative systematic review of the open dislocation, mini open, and arthroscopic surgeries for femoroacetabular impingement. *Arthroscopy* 2011;27:252–269.
- Botser IB, Smith TW Jr, Nasser R, Domb BG.** Open surgical dislocation versus arthroscopy for femoroacetabular impingement: a comparison of clinical outcomes. *Arthroscopy* 2011;27:270–278.
- Sampson TG.** Arthroscopic treatment of femoroacetabular impingement. *Tech Orthop* 2005;20:56–62.
- Bedi A, Galano G, Walsh C, Kelly BT.** Capsular management during hip arthroscopy: from femoroacetabular impingement to instability. *Arthroscopy* 2011;27:1720–1731.
- Beck M, Leunig M, Parvizi J, et al.** Anterior femoroacetabular impingement: part II. Midterm results of surgical treatment. *Clin Orthop Relat Res* 2004;418:67–73.
- Gupta A, Redmond JM, Hammarstedt JE, Schwindel L, Domb BG.** Safety measures in hip arthroscopy and their efficacy in minimizing complications: a systematic review of the evidence. *Arthroscopy* 2014;30:1342–1348.
- Heyworth BE, Shindle MK, Voos JE, Rudzki JR, Kelly BT.** Radiologic and intraoperative findings in revision hip arthroscopy. *Arthroscopy* 2007;23:1295–1302.
- Philippon MJ, Schenker ML, Briggs KK, et al.** Revision hip arthroscopy. *Am J Sports Med* 2007;35:1918–1921.
- Wright RW, Brand RA, Dunn W, Spindler KP.** How to write a systematic review. *Clin Orthop Relat Res* 2007;455:23–29.
- Pan H, Kawanabe K, Akiyama H, et al.** Operative treatment of hip impingement caused by hypertrophy of the anterior inferior iliac spine. *J Bone Joint Surg [Br]* 2008;90:677–679.
- Hetsroni I, Poulosides L, Bedi A, Larson CM, Kelly BT.** Anterior inferior iliac spine morphology correlates with hip range of motion: a classification system and dynamic model. *Clin Orthop Relat Res* 2013;471:2497–2503.
- Irving MH.** Exostosis formation after traumatic avulsion of the anterior inferior iliac spine: report of two cases. *J Bone Joint Surg [Br]* 1964;46:720–722.
- Rajasekhar C, Kumar KS, Bhamra MS.** Avulsion fractures of the anterior inferior iliac spine: the case for surgical intervention. *Int Orthop* 2001;24:364–365.
- Hetsroni I, Larson CM, Dela Torre K, et al.** Anterior inferior iliac spine deformity as an extra-articular source for hip impingement: a series of 10 patients treated with arthroscopic decompression. *Arthroscopy* 2012;28:1644–1653.
- de Sa D, Alradwan H, Cargnelli S, et al.** Extra-articular hip impingement: a systematic review examining operative treatment of psoas, subspine, ischiofemoral, and greater trochanteric/pelvic impingement. *Arthroscopy* 2014;30:1026–1041.
- Patti JW, Ouellette H, Bredella MA, Torriani M.** Impingement of lesser trochanter on ischium as a potential cause for hip pain. *Skeletal Radiol* 2008;37:939–941.
- Hatem MA, Palmer IJ, Martin HD.** Diagnosis and 2-year outcomes of endoscopic treatment for ischiofemoral impingement. *Arthroscopy* 2015;31:239–246.
- Taneja AK, Bredella MA, Torriani M.** Ischiofemoral impingement. *Magn Reson Imaging Clin N Am* 2013;21:65–73.
- Backer MW, Lee KS, Blankenbaker DG, Kijowski R, Keene JS.** Correlation of ultrasound-guided corticosteroid injection of the quadratus femoris with MRI findings of ischiofemoral impingement. *AJR Am J Roentgenol* 2014;203:589–593.
- Kim WJ, Shin HY, Koo GH, et al.** Ultrasound-guided prolotherapy with polydeoxyribonucleotide sodium in ischiofemoral impingement syndrome. *Pain Pract* 2014;14:649–655.
- Viala P, Vanel D, Larbi A, Cyteval C, Laredo JD.** Bilateral ischiofemoral impingement in a patient with hereditary multiple exostoses. *Skeletal Radiol* 2012;41:1637–1640.
- Ali AM, Whitwell D, Ostlere SJ.** Case report: imaging and surgical treatment of a snapping hip due to ischiofemoral impingement. *Skeletal Radiol* 2011;40:653–656.
- Safran M, Ryu J.** Ischiofemoral impingement of the hip: a novel approach to treatment. *Knee Surg Sports Traumatol Arthrosc* 2014;22:781–785.
- Ganz R, Slongo T, Turchetto L, et al.** The lesser trochanter as a cause of hip impingement: pathophysiology and treatment options. *Hip Int* 2013;23(suppl 9):S35–S41.
- Wilson MD, Keene JS.** Treatment of ischiofemoral impingement: results of diagnostic injections and arthroscopic resection of the lesser trochanter. *J Hip Preserv Surg* 2016;3:146–153.



35. **Albers CE, Steppacher SD, Schwab JM, Tannast M, Siebenrock KA.** Relative femoral neck lengthening improves pain and hip function in proximal femoral deformities with a high-riding trochanter. *Clin Orthop Relat Res* 2015;473:1378–1387.
36. **Jani L.** Die Entwicklung des Schenkelhalses nach der Trochanterversetzung. [The development of the femur neck after transposition of the trochanter]. *Arch Orthop Unfallchir* 1969;66:127–132.
37. **Macnicol MF, Makris D.** Distal transfer of the greater trochanter. *J Bone Joint Surg [Br]* 1991;73:838–841.
38. **Leunig M, Ganz R.** Relative neck lengthening and intracapsular osteotomy for severe Perthes and Perthes-like deformities. *Bull NYU Hosp Jt Dis* 2011;69(suppl 1):S62–S67.
39. **Anderson LA, Erickson JA, Severson EP, Peters CL.** Sequelae of Perthes disease: treatment with surgical hip dislocation and relative femoral neck lengthening. *J Pediatr Orthop* 2010;30:758–766.
40. **Shore BJ, Novais EN, Millis MB, Kim YJ.** Low early failure rates using a surgical dislocation approach in healed Legg-Calvé-Perthes disease. *Clin Orthop Relat Res* 2012;470:2441–2449.
41. **Zaltz I, Kelly BT, Hetsroni I, Bedi A.** The crossover sign overestimates acetabular retroversion. *Clin Orthop Relat Res* 2013;471:2463–2470.
42. **Bredella MA, Azevedo DC, Oliveira AL, et al.** Pelvic morphology in ischiofemoral impingement. *Skeletal Radiol* 2015;44:249–253.
43. **Johnson KA.** Impingement of the lesser trochanter on the ischial ramus after total hip arthroplasty. Report of three cases. *J Bone Joint Surg [Am]* 1977;59:268–269.
44. **Torriani M, Souto SC, Thomas BJ, Ouellette H, Bredella MA.** Ischiofemoral impingement syndrome: an entity with hip pain and abnormalities of the quadratus femoris muscle. *AJR Am J Roentgenol* 2009;193:186–190.
45. **Tosun O, Algin O, Yalcin N, et al.** Ischiofemoral impingement: evaluation with new MRI parameters and assessment of their reliability. *Skeletal Radiol* 2012;41: 575–587.
46. **Larson CM, Kelly BT, Stone RM.** Making a case for anterior inferior iliac spine/subspine hip impingement: three representative case reports and proposed concept. *Arthroscopy* 2011;27:1732–1737.
47. **Matsuda DK, Calipusan CP.** Adolescent femoroacetabular impingement from malunion of the anteroinferior iliac spine apophysis treated with arthroscopic spinoplasty. *Orthopedics* 2012;35:e460–e463.
48. **Amar E, Druckmann I, Flusser G, et al.** The anterior inferior iliac spine: size, position, and location. An anthropometric and sex survey. *Arthroscopy* 2013;5:874–881.